

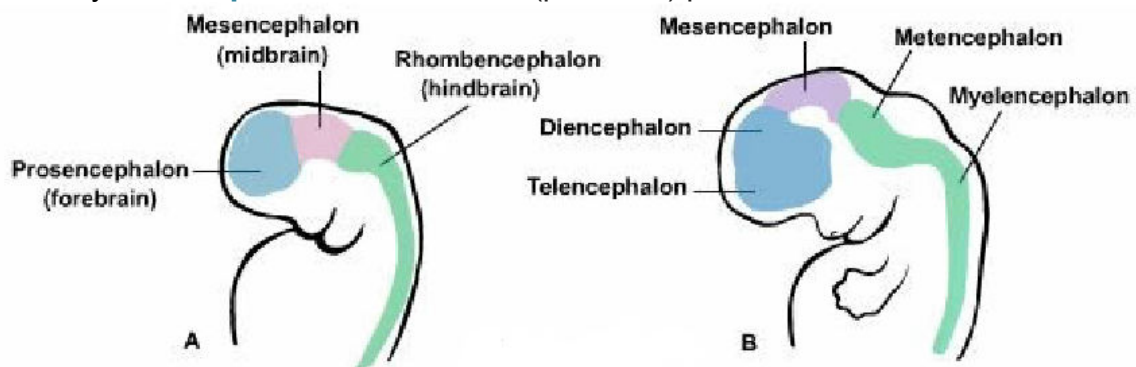
The Structure of the Brain

The structure of the brain can be explained in many different ways, which can cause confusion even when the main parts are listed. The following explanation of the brain structure can help to understand the division and structure of the brain.

The **Cerebrum** is the largest portion of the brain. It encompasses about two-thirds of the brain mass and lies over and around most of the structures of the brain. The layer of gray matter, about 2 to 4mm thickness, on the outer surface of the cerebrum is called the **Cerebral cortex**. The **Cerebrum** has both gray and white matter while the gray part of it is considered as the **Cerebral cortex**. The rest of the **Cerebrum** are **Subcortical Structures**.

The **neocortex** (6 layers) the largest part of the **Cerebral cortex** (90%); the other parts of the cerebral cortex are the **paleocortex** and **archicortex**, collectively known as the **allocortex** (3 or 4 layers). Also, there is the **periallocortex** – a transitional zone between the neocortex and the allocortex.

The **Telencephalon** is the embryonic structure from which the **Cerebrum** develops prenatally. **Diencephalon** is the caudal (posterior) part of the forebrain.



Lateral view of human embryo at the beginning of the 3rd (A) and 5th (B) week of gestation.

Forebrain (prosencephalon) includes:

- **Telencephalon**
- **Diencephalon**

Telencephalon includes:

Cerebral cortex: Frontal Lobe, Temporal Lobe, Parietal Lobe and Occipital Lobe

Subcortical Structures: Basal Ganglia, **Hippocampus** and **Amygdala** (parts of the **Limbic System**)

Corpus Collosum: connects the left and right cerebral hemispheres

Diencephalon containing:
Epithalamus

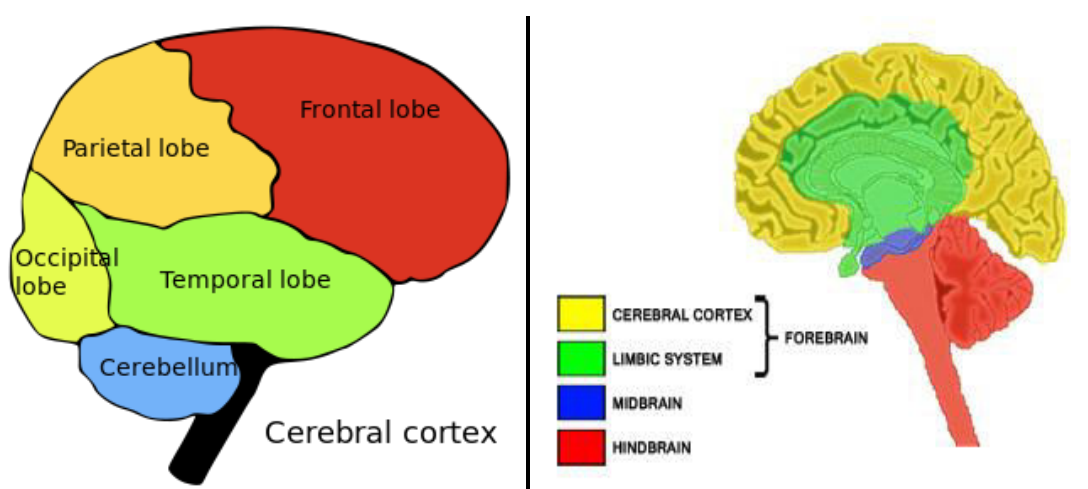
Thalamus
 Hypothalamus
 Ventral thalamus
 Third ventricle

The **Midbrain** (mesencephalon) consists of the Tectum and Tegmentum.

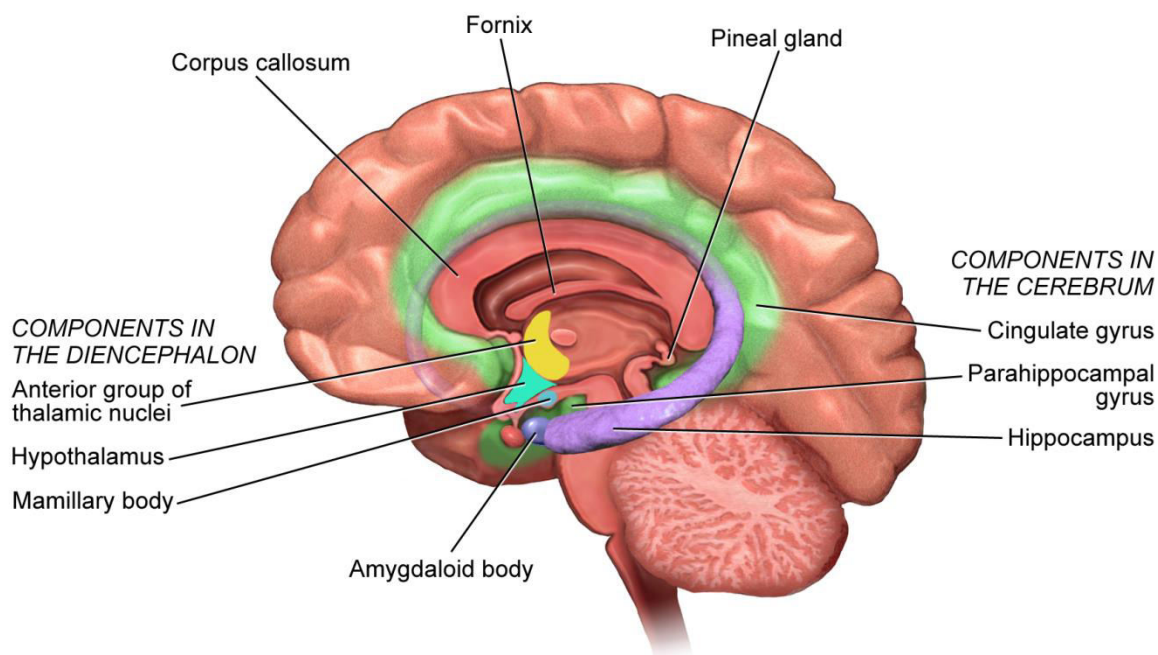
The **Hindbrain** (also called **Reptilian brain**) is made of the Cerebellum (little brain), Pons (metencephalon), Medulla Oblongata (myelencephalon) and the spinal cord

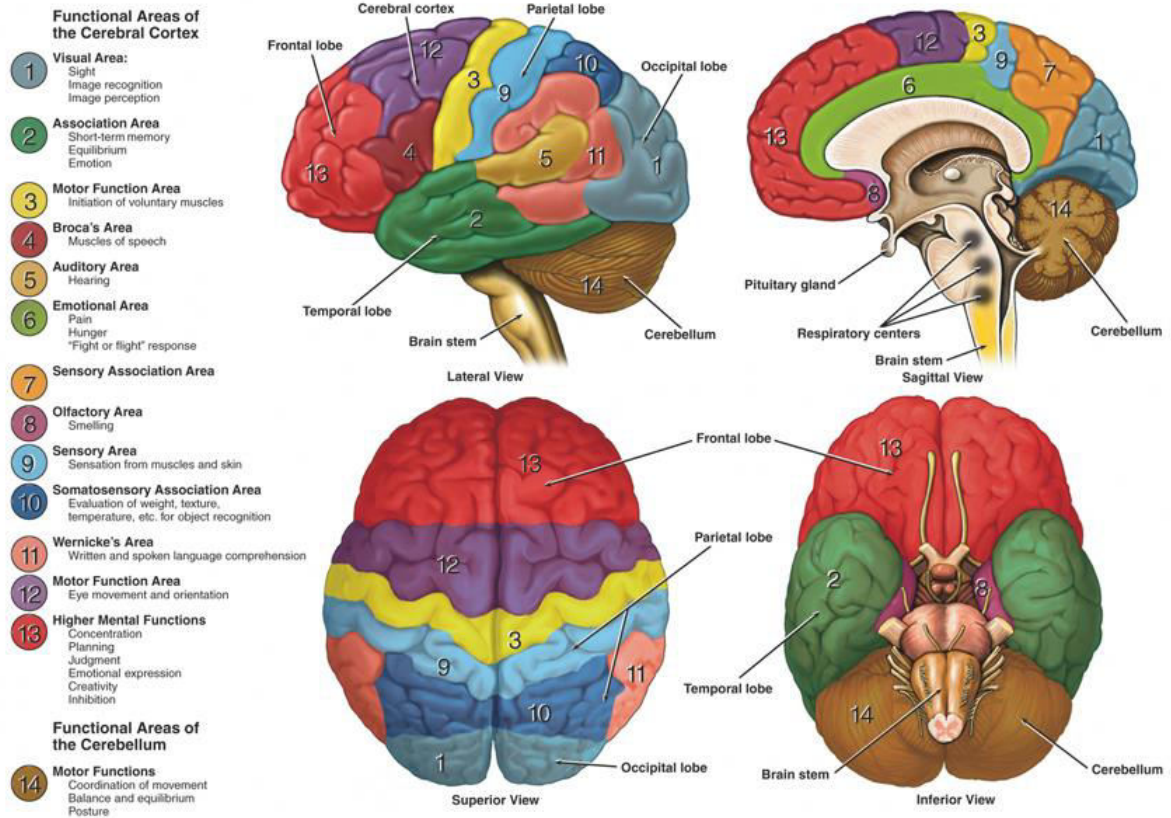
Limbic system contains the Hippocampus and Amygdala, Hypothalamus.

The **Brainstem** is underneath the limbic system. It includes **Midbrain** and **portions of the Hindbrain**. Particularly: Midbrain (mesencephalon), Medulla (myelencephalon) and Pons (metencephalon). It does NOT include the Cerebellum (little brain).



The Limbic System





Links to other pictures and explanations:

<http://www.columbia.edu/cu/psychology/courses/1010/mangels/neuro/anatomy/structure.html>

3D picture of the brain: <http://www.g2conline.org/2022>